

## Pathophysiological dilemmas of lipedema



E. Szél\*, L. Kemény, G. Groma<sup>1</sup>, G. Szolnoky<sup>1</sup>

Department of Dermatology and Allergology, University of Szeged, Faculty of Medicine, Koranyi fasor 6-8, 6720 Szeged, Hungary

### ARTICLE INFO

#### Article history:

Received 21 March 2014  
Accepted 11 August 2014

### ABSTRACT

Lipedema is a common, but often underdiagnosed masquerading disease of obesity, which almost exclusively affects females. There are many debates regarding the diagnosis as well as the treatment strategies of the disease. The clinical diagnosis is relatively simple, however, knowledge regarding the pathomechanism is less than limited and curative therapy does not exist at all demanding an urgent need for extensive research. According to our hypothesis, lipedema is an estrogen-regulated polygenetic disease, which manifests in parallel with feminine hormonal changes and leads to vasculo- and lymphangiopathy. Inflammation of the peripheral nerves and sympathetic innervation abnormalities of the subcutaneous adipose tissue also involving estrogen may be responsible for neuropathy. Adipocyte hyperproliferation is likely to be a secondary phenomenon maintaining a vicious cycle. Herein, the relevant articles are reviewed from 1913 until now and discussed in context of the most likely mechanisms leading to the disease, which could serve as a starting point for further research.

© 2014 Elsevier Ltd. All rights reserved.

### Introduction

More than 1.4 billion adults were overweight and more than half a billion were obese according to the WHO public data in 2008 [1]. Differential diagnostic purposes demand the discussion of obesity-related masquerading diseases. Regarding the physical and psychological conditions of patients suffering from altered subcutaneous fat deposition, these problems may be as severe as obesity. Large and continuously increasing efforts are made to help obese patients to regain their normal body weight, unlike in case of masquerading diseases, where the underlying pathomechanisms are poorly understood and effective treatments are not or hardly available. The etiology and pathophysiology of conditions with disproportional fatty deposits like lipodystrophies, multiple symmetric lipomatosis, Dercum's disease and lipedema have not been

clearly elucidated. Among these disorders, lipedema is likely to be one of the most common but often underdiagnosed conditions [2]. This review aims to outline the current knowledge and to give insightful ideas and theoretical clues regarding the presumed pathomechanism of lipedema.

#### Epidemiology of lipedema

Epidemiology of lipedema has been barely investigated. Child AH et al. estimated the minimum value of prevalence within the population as 1:72,000 [3]. Besides, according to a study of Foldi et al., prevalence of lipedema was up to 11% among women and postpubertal girls in their test group [4]. Forner-Cordero et al. reported 18.8% of the patients in their unit with enlargement of the lower limbs between 2005 and 2012 [5]. Among patients hospitalized for lymphatic disease, the proportion is estimated as 8–17% [6]. Lipedema is extremely rare in the male population, however, few cases with testosterone or growth hormone deficiency, or liver disease have been reported [3,7]. Children can also be affected. According to a recent study, 6.5% of infants with the referral diagnosis of lymphedema actually suffered from lipedema [8].

#### Diagnosis, types and stages of lipedema

For a proper diagnosis, Wold, Hines and Allen proposed the following six diagnostic criteria in 1951 [9] (Table 1).

Based on the involved body parts, five types of lipedema can be differentiated [10] (Table 2).

*Abbreviations:* ADRF, adipocyte-derived relaxing factor; Ang-1,2, angiotensin-1,2; BMP-2, bone morphogenetic protein-2; CART, cocaine- and amphetamine-regulated transcript; ER $\alpha$ , $\beta$ , estrogen receptor alpha, beta; HIF-1 $\alpha$ , hypoxia-inducible factor-1 alpha; IPC, intermittent pneumatic compression; NSD1, nuclear receptor binding SET domain protein 1; PIT-1, pituitary-specific transcription factor-1; PROX1, prospero-related homeobox1; SNS, sympathetic nerve system; TNF- $\alpha$ , tumor necrosis factor-alpha; VEGF, vascular endothelial growth factor; VEGF-C, vascular endothelial growth factor-C; VEGFR-3, vascular endothelial growth factor receptor-3; WAT, white adipose tissue;  $\alpha$ MSH, alpha-melanocyte-stimulating hormone.

\* Corresponding author. Tel.: +36 30 366 11 04, +36 62 545 259; fax: +36 62 545 954.

E-mail address: [szeledit@hotmail.com](mailto:szeledit@hotmail.com) (E. Szél).

<sup>1</sup> Groma G., PhD and Szolnoky G., M.D., PhD have contributed equally to this work.

**Table 1**  
**Diagnostic criteria of lipedema.**

1. Lipedema merely affects women and appears by the third decade of life
2. Bilateral and symmetrical fat deposits develop downward from the hips, while the feet are usually spared
3. Non-pitting edema
4. Affected subcutaneous regions are tender, painful and characterized by easy bruising
5. Resistance to diet and stimulation of backflow by the elevation of the extremities
6. Increased vascular fragility

**Table 2**  
**Types of lipedema.**

- Type I: Pelvis, buttocks and hips  
 Type II: Buttocks to knees, with formation of folds of fat around the inner side of the knee  
 Type III: Buttocks to ankles  
 Type IV: Arms (rare, approximately 3% of all cases) [86]  
 Type V: Lower leg

**Table 3**  
**Stages of lipedema.**

- Stage 1: Normal skin surface with enlarged hypodermis  
 Stage 2: Uneven skin with indentations in the fat, larger mounds of tissue grow as unencapsulated masses, lipomas and angiolipomas  
 Stage 3: Large extrusions of tissue causing deformations especially on the thighs and around the knees  
 Stage 4: Lipedema with lymphedema

Lipedema can progress through four stages [2,11] (Table 3).

#### Therapeutical approaches

Primary options comprise lymphatic decongestive therapy, physiotherapeutic exercises, pain control, psychological support and liposuction. Occasionally, medications can also be considered: beta-adrenergic agonist for capillary leak syndrome, glucocorticosteroids for swelling and pain, cimetidine and beta glucan to improve the impaired local immune response due to edema [12], short-course of diuretics or selenium for lipedema with concomitant lymphedema [13]. Decongestive lymphatic therapy including manual lymphatic drainage, physical exercise, multilayered and multicomponent compression bandaging and meticulous skin care is the standard conservative approach for lipedema treatment [5]. Complex form of this decongestive lymphatic therapy has also been shown to decrease bruising, one of the hallmarks of lipedema [14]. Physiotherapy can also be combined with intermittent pneumatic compression (IPC) improving venous flow and decreasing lymph production [15]. However, it is doubtful whether IPC leads to additional improvement [16]. Another physiotherapeutical method, shock wave therapy has been found to reduce girth circumference and oxidative stress and to reshape body contour [17]. Liposuction is usually a temporal solution [18,19] A precise summary of recommended treatments has been reported by Herbst [2].

#### Hypothesis of the pathomechanism of lipedema

Lipedema is a severe but often underdiagnosed disease [2], however, according to our recent knowledge, generally accepted, evidence based theory for the pathomechanism does not exist, which evoked urgent need for hypothetic issues. In the background of lipedema, polygenetic susceptibility is suspected, which may

manifest in parallel with feminine hormonal changes. Several gene candidates playing a role in vasculo- or lymphangiogenesis and being under the influence of estrogen are supposed to be responsible for the primary endothelial barrier dysfunction and lymphangiopathy. Estrogen-mediated central imbalance of weight control and disturbed lipogenesis-lipolysis through partly genetic, body region specific peripheral effects could be involved in the pathogenesis. In addition, estrogen also has a pivotal role in the region-specific sympathetic innervation of the subcutaneous adipose tissue therefore we hypothesize innervation abnormalities and concomitant inflammation of sensory nerves in the background of neuropathy. Increased amount of adipose tissue might not be the initial step, rather the consequence of leaky lymphatics starting a vicious cycle and resulting in secondary alterations in blood and lymphatic (micro)circulation.

#### Genetic background: is lipedema an inherited condition?

A suspected genetic background was reviewed by Herbst [2]. In up to 60% of patients, lipedema was suggested to be an inherited condition [20]. Based on a clinical report, studying 330 family members, a possible autosomal dominant inheritance with incomplete penetrance was suspected, however, exact genes involved in lipedema were not identified here [3]. Nevertheless, several studies on different animal models provided many possible genes, which could potentially be involved in the manifestation of the disease. A study by Harvey et al. on a new model for adult-onset obesity and lymphatic vascular disease, mice with functional inactivation of a single allele of the homeobox gene PROX1, reported leaky lymphatics and consequent obesity [21]. In another animal model of hereditary lymphedema, mice with VEGFR-3 heterozygous inactivating missense mutation have hypoplastic dermal lymphatics and exhibit thickening of the subcutaneous adipose tissue [22,23]. Another possible candidate, which may play a role in the pathomechanism is PIT-1 gene. Mutation of PIT-1 was identified in a 23-year-old male and his mother. In this family, short stature and swelling of the legs affected women through four generations [24]. It is consistent with the findings of Foldi et al. who observed a higher incidence of lipedema after surgery for pituitary adenomas [4]. González-Parra and colleagues reported that changes in circulating levels of sex steroids modulate the expression of PIT-1 in the anterior pituitary gland [25]. BMP-2 is regulated by estrogen [26], able to cause inflammatory reaction with edema [27], stimulates adipogenesis [28] and has been reported to cause acute epidural lipedema [29]. NSD1 mutation is known to be associated with Sotos syndrome [30], however, it may be also responsible for the estrogen-mediated lipedema formation. These studies may represent a possible link between the genetic background and the role of estrogen in the development of lipedema.

#### Is the pathogenesis of lipedema hormonally influenced?

Estrogen has a direct effect on white adipose tissue through its estrogen receptors (ER $\alpha$ , $\beta$  and G protein-coupled estrogen receptors) [31]. Considering the difference of androgenic and gynoid adiposity, this effect is likely to be body region-specific. The background mechanism was discussed in a study where an intravenous bolus of conjugated estrogen led to a lower level of decrease in basal lipolysis of the abdominal than of the femoral region [32]. A study of Gavin and coworkers may explain this phenomenon: they found decreased ER $\alpha$  and increased ER $\beta$  protein level in the gluteal region of overweight-to-obese premenopausal women compared to the level of the abdominal adipose tissue and also observed that the waist-to-hip ratio was inversely related to gluteal ER $\beta$  protein and directly related to gluteal ER $\alpha$ /ER $\beta$  ratio

[33]. These results indicate that the distinct ER pattern in the abdominal and the gluteal subcutaneous tissue may lead to the difference observed in estrogen-mediated lipid metabolism. Based on these findings, one could raise the following questions: is there an alteration of ER pattern of lipedematous adipocytes? Alternatively, if the receptor distribution is normal, is there a defect in the signaling pathway of ERs? In addition to possible abnormalities in lipolysis, is lipogenesis also impaired? A recent review summarized the ER mediated lipid metabolism [34]. Studies of postmenopausal women revealed that the expression of genes involved in lipogenesis in general, i.e. acetyl-coenzyme A carboxylate- $\alpha$  and - $\beta$ , sterol regulatory element binding protein 1c, stearoyl-CoA desaturase, lipoprotein lipase, fatty acid synthase, fatty acid desaturase and peroxisome proliferator activated receptor- $\gamma$  in particular, was reduced following estrogen treatment [35,36]. In postmenopausal state, when the ovaries stop producing estrogen, it is synthesized extragonadally, including the adipose tissue and acts as a paracrine or intracrine factor [37]. It is important to highlight the special distribution of accumulated fat in lipedematous patients, i.e. almost exclusive involvement of the lower body part and further on, why lipedematous tissue might limitedly respond to physical exercise [2]. In a study of 17 premenopausal women, a standardized submaximal physical exercise for fifteen minutes increased the glycerol content (a marker for lipolytic activity of the subcutaneous tissue) more in the abdominal than in the gluteal region. After local estrogen perfusion, thirty minutes of submaximal exercise resulted in a significantly lower increase in glycerol content in the gluteal region compared to the control group without estrogen treatment at the abdominal area, and also showed similar tendency, which was not significant compared to the estrogen-treated abdominal region. [33]. As women reach menopause and the blood estrogen level starts declining, alterations in energy homeostasis leading to increased intraabdominal body fat accumulation also occur [38]. Therefore, dysfunction of this “switching mechanism” could represent an important part of the pathomechanism of lipedema. Regardless of “hormonal age”, estrogen may directly regulate both

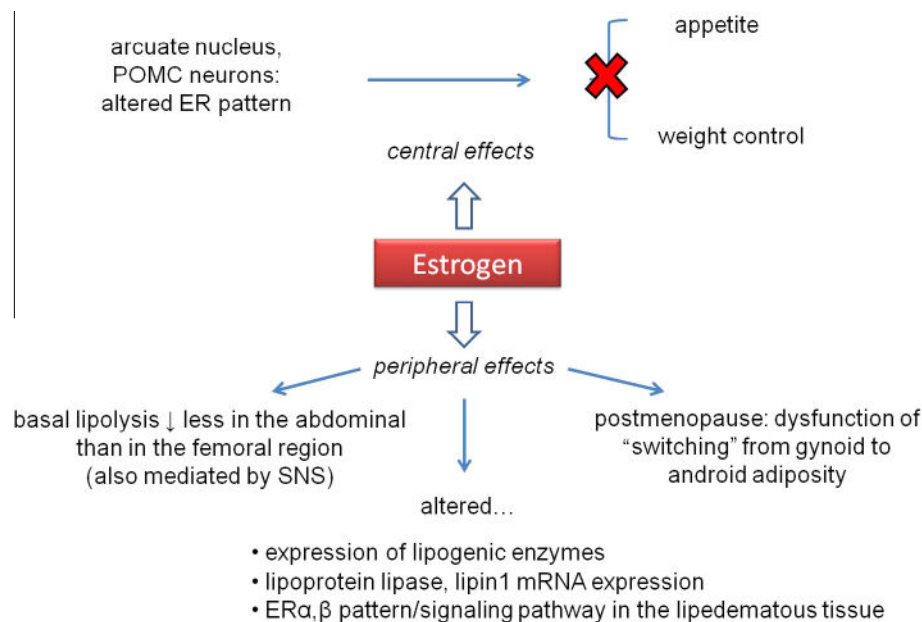
lipogenesis and lipolysis locally through modulating lipoprotein lipase activity and Lipin 1 mRNA expression [34].

Estrogen also acts as a central mediator for food intake and energy expenditure in the hypothalamus [34]. Particularly, ER $\alpha$  is expressed mainly by the pro-opiomelanocortin neurons of the arcuate nucleus [39], and these neurons are crucial in the regulation of the decrease in food intake via the secretion of  $\alpha$ MSH [40,41]. When ER $\alpha$  gene was silenced or selectively deleted in specific neurons of the ventromedial hypothalamus, mice had reduced sensitivity to estrogen-induced weight loss [39,42]. If an altered ER pattern also exists centrally (not only in the adipose tissue), this may provide a hypothetic explanation for difficulties in weight loss in patients suffering from lipedema [2]. The experience is to be elucidated why some patients can lose weight from almost everywhere except for the lipedematous area [43]. A summary of the potential mechanism of action of estrogen is shown by Fig. 1.

### Cause-and-causative relationships: the role of impaired vascular and lymphatic circulation of the lower legs

#### Vasculopathy

Microangiopathy is one of the early histological features of the lipedemic pathomechanism [4], which may be due to the primary defect of the endothelial barrier function. Alternatively, hypoxia may result in increased fragility similarly to diabetic retinopathy [44]. Angiogenesis have several stimulators, including VEGF, Ang-1 and Ang-2 among others. In breast cancer, it has been suggested that VEGF generates leaky, hemorrhagic, immature vessels [45]. As tissue expansion requires imbalanced vascularity, i.e. relatively increased expression of angiogenic factors compared to the anti-angiogenic molecules, interventions on this area may have not only theoretical but also clinical significance. It has been shown that angiogenesis inhibitors including angiostatin and endostatin could prevent obesity in genetically modified mice [46]. Similarly, local VEGF inhibition in the adipose tissue may represent a likely



**Fig. 1. Potential mechanism of action of estrogen in lipedema.** Central effects: altered ER (estrogen receptor) pattern of the POMC (pro-opiomelanocortin) neurons in the hypothalamic arcuate nucleus may lead to uncoupled regulation of appetite and weight control. Peripheral effects: estrogen leads to less decrease in basal lipolysis in the abdominal than in the femoral region. Any lesions of the SNS (sympathetic nerve system), which is also involved in the regulation of lipolysis, may contribute to adipose tissue accumulation. In addition, not only lipolytic, but lipogenic mechanisms can also be affected, including altered expression of lipogenic enzymes, lipoprotein lipase and lipin mRNA. Alterations of the ER $\alpha$ , $\beta$  pattern or their signaling pathway may also exist on the periphery. In postmenopause, absence of the physiological “switch” from gynoid to android adiposity may explain the appearance of lipedema.

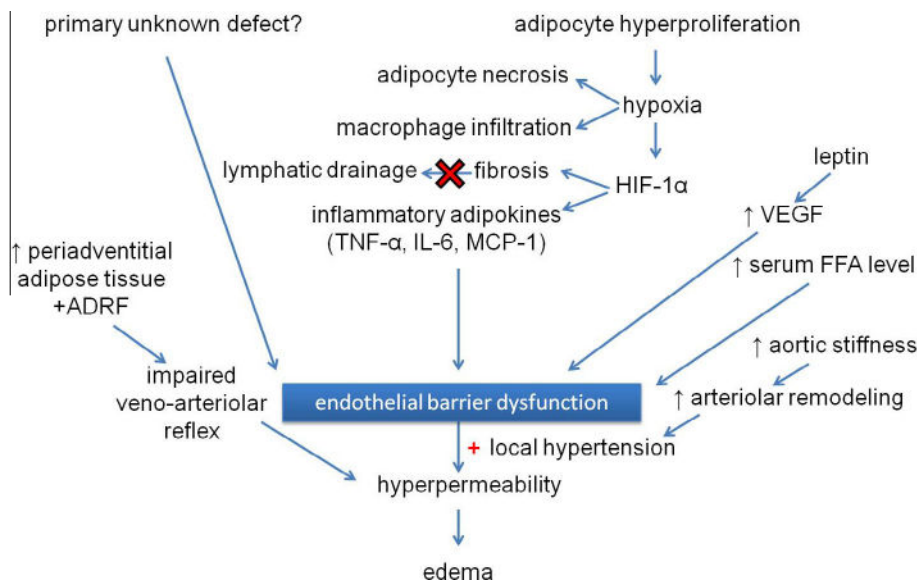
therapeutic approach in lipedema. However, this may lead to complications like increased level of inflammation due to hypoxia [47]. The same workgroup also mentioned antidiabetic drugs influencing angiogenesis: thiazolidindione derivatives, which increase vasculogenesis on a tissue specific manner [48] and metformin known to have a beneficial effect through reducing angiogenesis [49]. These observations may pose important message regarding lipedematous patients also treated with diabetes. Oxidative stress in lipedema has been shown in a study of shock wave therapy, where increased serum concentrations of malondialdehyde (marker for lipid peroxidation) and plasma protein carbonyls (products of oxidized proteins) were detected [17]. On the other hand, hypoxia due to adipocyte hyperproliferation may cause adipocyte necrosis, production of inflammatory cytokines and macrophage infiltration [50]. Increased free fatty acid level [51,52] can lead to endothelial dysfunction and altered transendothelial transport. In a poor oxygen environment, HIF-1 $\alpha$ -induced fibrosis [53] may also develop, compromising the compensatory lymphatic drainage. Leptin also moderates angiogenesis under hypoxic conditions, it has direct effect on endothelium and also enhances VEGF production [54,55]. In addition to hypoxia, two further effects may also be involved in the manifestation of microangiopathy: adipose hyperplasia and local hypertension in the capillaries, leading to hyperpermeability. At the same time, aortic stiffness [44] and increased peripheral vascular resistance with arteriolar remodeling may also develop. Role of estrogen in abnormal capillary formation cannot be excluded. In a study of 96 cases of patients with invasive ductal breast carcinoma, under the influence of estrogen, decreased anti-apoptotic activity was found in endothelial cells in contrast to tumor cells where the opposite effect was observed [45]. Regardless of the causes, increased microvascular permeability to proteins enhances edema formation; however, it is unclear, whether the lipedematous fluid is primarily derived from the blood or from the lymphatic vessels.

On the level of large vessels, an autoregulatory mechanism, veno-arterial reflex against edema formation [56] was shown to be impaired in lipedema [4]. Adipocyte-derived relaxing factor

(ADRF) may be a putative mediator in the background. ADRF is released from the periadventitial adipose tissue and activates voltage-dependent potassium channels that hyperpolarize the membrane of smooth muscle cells [57]. If the periadventitial adipose tissue also starts proliferating in lipedema, relative abundance of ADRF may impede increase in the pre-capillary vascular resistance, i.e. the veno-arterial reflex mechanism. In addition, an intrinsic connective tissue defect has also been suspected, which may cause musculo-facial insufficiency [58] and loss of skin elasticity. These could hinder the venous leg pump, therefore the pressure of the veins at the dorsum of the foot cannot drop in parallel with the change from standing to walking position. To raise the interstitial pressure in a skin with loss of elasticity, more fluid is required resulting in an impaired compensatory mechanism of the lymph vessels against edema formation [4]. Gravitation induced elevation of pressure itself may damage both blood and lymphatic capillaries in the lower extremities being in vertical position for a long time on daily basis, for several years, which may also have a role in the formation of lipedematous body shape (“stove-pipe legs” and uninvolved upper body part) [2]. Fig. 2 summarizes the potential mechanisms leading to vasculopathy.

#### Lymphangiopathy

Lipedema is distinguished from lymphedema, where the primary cause is believed to be the impaired lymphatic system. Given that these two entities may coexist [2] and the alterations of the lymphatic vasculature in lipedema have not yet been studied more in details, one should also consider the putative role of this phenomenon. Amann-Vesti and colleagues tested twelve lipedematous patients with fluorescence microlymphography and found multiple microlymphatic aneurysms at the thigh, the ankle region or the foot [59]. Based on the observation of Foldi et al., functional and morphological abnormalities of the lymph capillaries are the indicators of impaired lymph formation in lipedema [4]. Enlarged lymphatic vessels with beaded appearance were found by MR lymphangiography, which may indicate a subclinical lipo-lymph-



**Fig. 2. Possible mechanisms leading to vasculopathy, mainly endothelial barrier dysfunction in lipedema.** Endothelial barrier dysfunction can result from (a) primary unknown genetic defect(s) or adipocyte hyperproliferation with the subsequent downstream mechanisms. Adipocyte hyperproliferation may compress capillaries leading to hypoxia and a consequent adipocyte necrosis, production of cytokines resulting in macrophage infiltration. Among these cytokines, HIF-1 $\alpha$  (hypoxia inducible factor-1 alpha) induces fibrosis with a subsequent impaired lymphatic drainage, and production of inflammatory adipokines (TNF- $\alpha$ : tumor necrosis factor-alpha, IL-6: interleukin-6, MCP-1: monocyte-chemotactic protein-1) causing endothelial barrier dysfunction, which can be aggravated by the leptin induced VEGF (vascular endothelial growth factor) production and increased serum FFA (free fatty acid) level. The damaged barrier is hyperpermeable. Fluid extravasation may be enhanced by impaired veno-arteriolar reflex caused by accumulation of periadventitial adipose tissue and production of ADRF (adipocyte-derived relaxing factor). In addition, increased aortic stiffness with concomitant arteriolar remodeling leading to local hypertension may also have a role in edema formation.

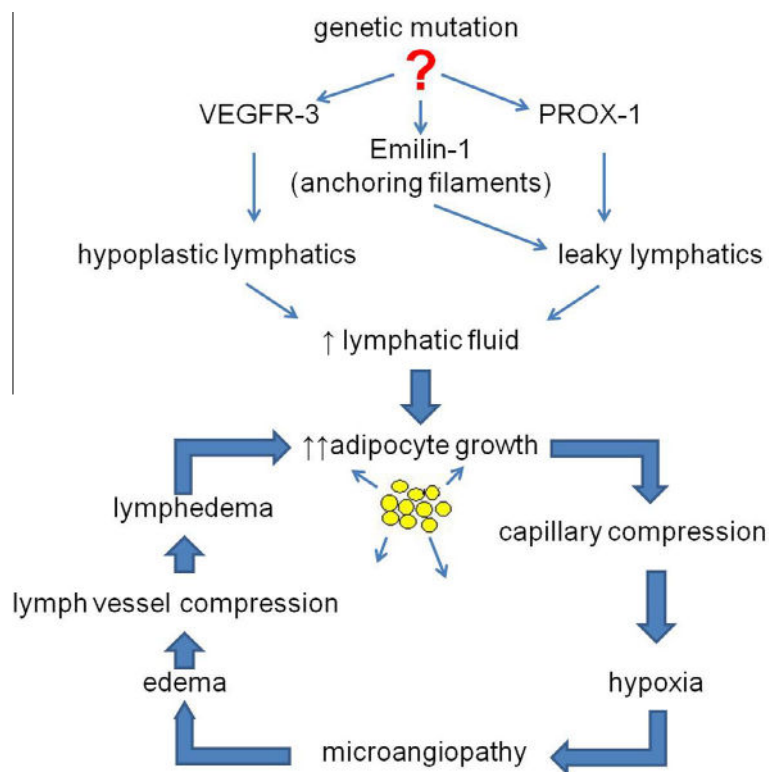
dema state [60]. Wollina and colleagues found podoplanin negativity in the ectatic subcutaneous vessels of two patients with lipolymphedema [61]. The next studies indicate the effect of lymphatic fluid on fat accumulation. According to Brorson et al., liposuction can be an effective treatment for patients with fat accumulation due to lymphedema [62]. Nougues and colleagues studying rabbit adipocytes observed enhanced differentiation and lipid accumulation caused by mesenteric lymph and chylomicrons in the culture medium [63]. Further animal studies indicate that lymphangiogenic defects cause increased fat deposition [21,22]. It is extremely challenging to determine, whether there is a secondary lymphatic defect, i.e. a subtle, persistent and continually aggravating mechanical obstruction of the lymphatic capillaries due to the expansion of adipose tissue [64], or a primary genetic cause. Schulte-Merker and co-workers reviewed numerous knock-out genes involved in lymphatic morphogenesis in mice [65]. If we assume an early damage in the lymphatic capillaries, an elastic microfibril-associated protein, Emilin 1 must be highlighted, since the lack of this protein leads to the reduction of anchoring filaments, resulting in impaired lymph drainage and increased lymph leakage [66]. Adipocytes during expansion also produce lymphangiogenic factors, like VEGF-C [67], causing lymphatic hyperplasia [68]. As mentioned above, adipocytes start to grow robustly in the presence of lymphatic fluid [69], consequently, increased amount of fat may cause the compression of capillaries resulting in hypoxia, followed by microangiopathy, edema formation and finally, the manifestation of lymphedema. Further damage of the lymphatic system leads to additional stimulation of adipocyte growth, closing the vicious cycle (Fig. 3).

### Neuropathy in lipedema

As a part of the diagnostic criteria (Table 1), the affected subcutaneous regions are often tender and painful, which may cause difficulties in the application of bandaging, however, this pain is improved after mild manual lymphatic drainage [70] and liposuction [64].

In a single case report, reduced amplitude of sensory nerve action potential shown by nerve conduction study was attributed to: (1) mechanical forces (presence of serious edema and increased amount of subcutaneous adipose tissue) and (2) biochemical effects, i.e. the inflammation of sensory nerves derived from sympathetic nerve fibers distributing among adipocytes. In case if microangiopathy also exists, disturbance of protopathic sensibility may be aggravated due to the inappropriate blood supply of the peripheral nerves [70]. Taking into consideration that accumulation of subcutaneous adipose tissue is also involved in the pathogenesis of lipohypertrophy, which lacks both edema and pain [64], mechanical stimulus by itself fails to explain the neurological background.

The following observations discuss the abnormal innervation theory leading to increased adipose tissue mass. Mueller examined a paraplegic patient with great adipose tissue mass in the lower half of the torso. This finding motivated him to compare the artificially paralyzed and intact legs of guinea pigs, which revealed greater amounts of white adipose tissue (WAT) on the paralyzed compared to the uninvolved legs [71]. In addition, not only secondary, but also primary neurons can be affected based on animal models [72,73].



**Fig. 3. Hypothesis of genetic background and lymphangiopathy in lipedema.** Genetic mutation has not been identified in lipedema, however, investigation of VEGFR-3 (vascular endothelial growth factor-3) causing hypoplastic lymphatic vessels, PROX-1 (prospero-related homeobox-1) and Emilin-1 leading to the formation of leaky lymphatics could serve as potential targets based on previous animal studies [21–23,66]. Lymphatic fluid accumulation enhances adipocyte growth, which causes hypoxia by the compression of capillaries. Hypoxia induces microangiopathy and the following fluid extravasation leads to the development of edema. Increased amount of interstitial fluid leads to the compression of lymph vessels triggering the appearance of lymphedema, which further aggravates adipocyte growth.

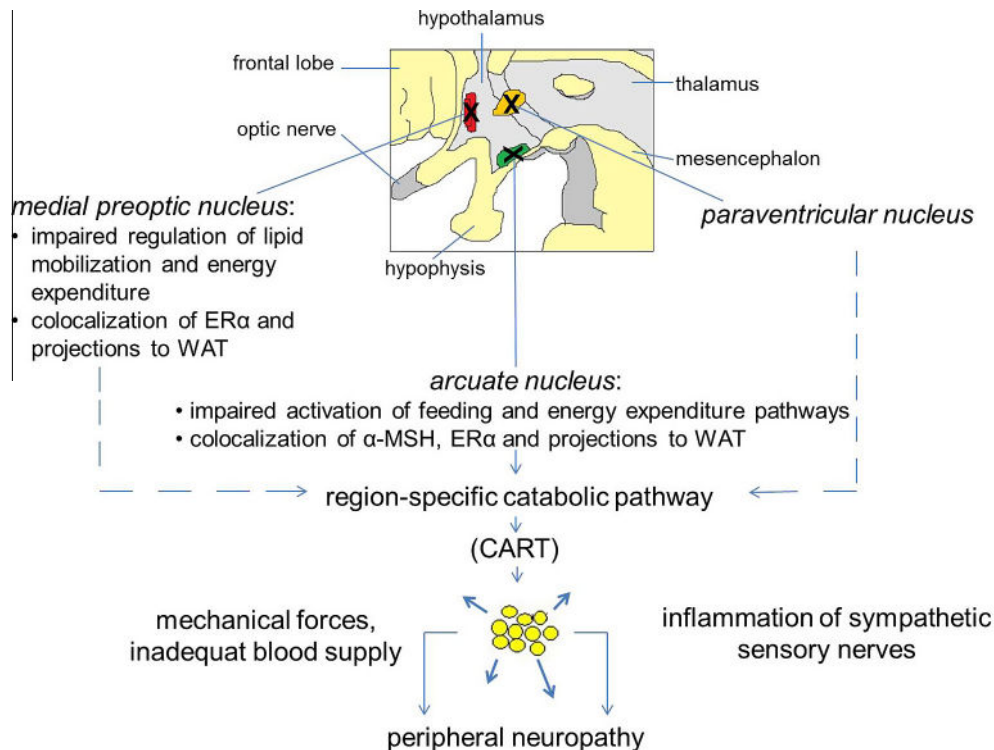
A study of Youngstrom et al. showed that the sympathetic denervation of rat inguinal WAT resulted in increased fat pad mass and fat cell number. Moreover, it happened during the artificial “short day exposure” modeling winter-like period with naturally decreased food intake, which may resemble the diet period of lipedematous patients. They also described a region specific WAT depletion characterized by earlier decline of the epididymal WAT mass than the inguinal WAT. Behind this observation, a region specific SNS regulation was suspected [74]. By the comparison of the relative proportion of neurons projecting to abdominal, inguinal subcutaneous and both fat deposits, the least abundance of neurons going exclusively to inguinal WAT were found in male rats, but this difference was not present in a number of brain nuclei in females [75]. Interestingly, they have also studied whether these neurons contain sex steroid receptors. Among the identified nuclei projecting to inguinal WAT and expressing ER $\alpha$ , the arcuate nucleus and the nucleus of the solitary tract have paramount roles in the integration of nutrient availability and activation of feeding and energy expenditure pathways [76–78]. The colocalization of ER $\alpha$  and neurons projecting to inguinal WAT was most prominent in the medial preoptic nucleus involved in the regulation of lipid mobilization and energy expenditure, regardless of food intake [79,80]. An additional finding was the special neuronal pattern: “private lines” to individual fat pads and coordinating collateral neurons, the so-called “command neurons”. In this network, differences in the expression of certain neurotransmitters and receptors were found. The most relevant receptor was the ER $\alpha$  [75]. It is consistent with the observation of Lazzarini and his colleague and Clegg et al., who reported that sympathetic innervations of certain adipose tissue regions are involved in body weight reduction and fat distribution mediated by estrogen, mainly via ER $\alpha$  [81,82].

Leptin and insulin receptors were also found on neurons projecting to WAT [75] and colocalization of ER $\alpha$  and leptin receptors had been previously shown [83]. Clegg et al. elucidated the functional role of the three receptors: leptin and insulin sensitivity are modulated by estrogen, presumably by an ER $\alpha$ -driven mechanism in the hypothalamus [82]. The last mediator can be a catabolic peptide, cocaine- and amphetamine-regulated transcript (CART) [75]. When it comes to lipedema, molecular disturbance can occur at any points of this catabolic neuronal pathway accessing the subcutaneous adipose tissue of the lower body part. Fig. 4 summarizes the pathophysiological mechanisms associated with neuropathy in lipedema.

### Further ideas

Lipid composition is another barely investigated feature in lipedema. Stallworth et al. revealed altered fatty acid pattern and significant amounts of lipids in plasma and adipose tissue studying fourteen patients [84], but no further information has been found about this issue in the literature until now.

Regarding several features, lipedema may also have an etiological connection with another relatively rare disease, lipedematous alopecia. Only 24 cases were reported until 2007, including exclusively females, which could suggest the role of the hormonal system. [85]. Fair et al. found edematous and disintegrated subcutaneous adipose tissue in a patient with lipedematous alopecia resembling the histological pattern of lipedema. Hair abnormality is another feature of lipedematous alopecia as well as of chronic lymphedema of the extremities, however, it has not been reported in lipedema [86].



**Fig. 4. Neuropathy in lipedema.** Impairment at different levels of the sympathetic nerve system is suggested in the background of lipedematous neuropathy. In the hypothalamus, potential damage of three nuclei is in focus: the medial preoptic nucleus, the arcuate nucleus and the paraventricular nucleus. The medial preoptic nucleus is responsible for the regulation of lipid mobilization and energy expenditure, in addition, ER $\alpha$  (estrogen receptor  $\alpha$ ) and projections to WAT (white adipose tissue) are also colocalized here. Co-found of  $\alpha$ -MSH ( $\alpha$ -melanocyte-stimulating hormone), ER $\alpha$  and projections to WAT was described in the arcuate nucleus [75,79], which organizes the feeding and energy expenditure pathways. Region-specific projections to WAT start from all of these three nuclei. These projections form a catabolic pathway with a possible mediator, CART (cocaine- and amphetamine-regulated transcript). Lesion of this catabolic pathway may lead to region-specific subcutaneous adipose tissue accumulation. However, peripheral neuropathy cannot be explained exclusively by mechanical forces (compression). Microangiopathy and inflammation of sympathetic sensory nerves may also contribute to this phenomenon.

## Conclusion

As a summarized concept of the pathomechanism of lipedema has not existed until now even on hypothetic level, we attempted to find causal relationships relying on currently available literature data. If any experimental evidence supports this theory, it will lead to the better understanding of the development of lipedema and be able to provide effective, long-lasting therapy for patients.

## Conflict of interest

All authors have approved the manuscript and agreed with submission to the Medical Hypotheses. The authors have no conflicts of interest to declare.

## Acknowledgements

Creation of this manuscript was supported by the European Union and the State of Hungary, co-financed by the European Social Fund in the framework of TÁMOP 4.2.4. A/2-11-1-2012-0001 'National Excellence Program'.

## References

- [1] WHO, 10 facts on obesity <<http://www.who.int/features/factfiles/obesity/facts/en/index1.html>>, [date of access: 09/03/2014].
- [2] Herbst KL. Rare adipose disorders (RADs) masquerading as obesity. *Acta Pharmacol Sin* 2012;33:155–72.
- [3] Child AH, Gordon KD, Sharpe P, et al. Lipedema: an inherited condition. *Am J Med Genet* 2010;152A:970–6.
- [4] Földi E, Földi M, Kubik S (Eds.), *Textbook of lymphology (in English)*. Munich, Amsterdam, New York: Elsevier; 2005. p. 418–27. ISBN 0-9729535-0-7, [Chapter 9: E. Földi and M. Földi: Lipedema].
- [5] Forner-Cordero I, Szolnoky G, Forner-Cordero A, Kemény L. Lipedema: an overview of its clinical manifestations, diagnosis and treatment of the disproportional fatty deposition syndrome – systematic review. *Clin Obes* 2012;2:86–95.
- [6] Meier-Vollrath I, Schneider W, Schmeller W. Lipödem: Verbesserte Lebensqualität durch Therapiekombination. *Deutsches Ärzteblatt* 2005;102:1061–7.
- [7] Chen SG, Hsu SD, Chen TM, Wang HJ. Painful fat syndrome in a male patient. *Br J Plast Surg* 2004;57:282–6.
- [8] Schook CC, Mulliken JB, Fishman SJ, Alomari AI, Grant FD, Greene AK. Differential diagnosis of lower extremity enlargement in pediatric patients referred with a diagnosis of lymphedema. *Plast Reconstr Surg* 2011;127:1571–81.
- [9] Wold LE, Hines Jr EA, Allen EV. Lipedema of the legs; a syndrome characterized by fat legs and edema. *Ann Intern Med* 1951;34:1243–50.
- [10] Meier-Vollrath I, Schneider W, Schmeller W. Das Lipödem: neue Möglichkeiten der Therapie. *Schweiz Med Forum* 2007;7:150–5.
- [11] Meier-Vollrath I, Schmeller W. Lipoedema – current status, new perspectives. *J Dtsch Dermatol Ges* 2004;2:181–6.
- [12] Greer KE. Lipedema of the legs. *Cutis* 1974;14:98.
- [13] Bruns F, Micke O, Bremer M. Current status of selenium and other treatments for secondary lymphedema. *J Support Oncol* 2003;1:121–30.
- [14] Szolnoky G, Nagy N, Kovács RK, Dósa-Rácz E, Szabó A, Bársony K, et al. Complex decongestive physiotherapy decreases capillary fragility in lipedema. *Lymphology* 2008;41:161–6.
- [15] Partsch H, Flour M, Smith PC; International Compression Club. Indications for compression therapy in venous and lymphatic disease consensus based on experimental data and scientific evidence. Under the auspices of the IUP. *Int Angiol* 2008;27:193–219.
- [16] Szolnoky G, Borsos B, Bársony K, Balogh M, Kemény L. Complete decongestive physiotherapy with and without pneumatic compression for treatment of lipedema: a pilot study. *Lymphology* 2008;41:40–4.
- [17] Siems W, Grune T, Voss P, Brenke R. Anti-fibrosclerotic effects of shock wave therapy in lipedema and cellulite. *BioFactors* 2005;24:275–82.
- [18] Peled AW, Slavin SA, Brorson H. Long-term outcome after surgical treatment of lipedema. *Ann Plast Surg* 2012;68:303–7.
- [19] Rapprich S, Dingler A, Podda M. Liposuction is an effective treatment for lipedema – results of a study with 25 patients. *J Dtsch Dermatol Ges* 2011;9:33–40.
- [20] Schmeller W, Hueppe M, Meier-Vollrath I. Tumescence liposuction in lipedema yields good long-term results. *Br J Dermatol* 2012;166:161–8.
- [21] Harvey NL, Srinivasan RS, Dillard ME, et al. Lymphatic vascular defects promoted by Prox1 haploinsufficiency cause adult-onset obesity. *Nat Genet* 2005;37:1072–81.
- [22] Karkkainen MJ, Saaristo A, Jussila L, et al. A model for gene therapy of human hereditary lymphedema. *Proc Natl Acad Sci USA* 2001;98:12677–82.
- [23] Mäkinen T, Jussila L, Veikkola T, et al. Inhibition of lymphangiogenesis with resulting lymphedema in transgenic mice expressing soluble VEGF receptor-3. *Nat Med* 2001;7:199–205.
- [24] Bano G, Mansou S, Brice G, et al. Pit-1 mutation and lipoedema in a family. *Exp Clin Endocrinol Diabetes* 2010;118:377–80.
- [25] González-Parra S, Chowen JA, García-Segura LM, Argente J. In vivo and in vitro regulation of pituitary transcription factor-1 (Pit-1) by changes in the hormone environment. *Neuroendocrinology* 1996;63:3–15.
- [26] Okazaki R, Inoue D, Shibata M, et al. Estrogen promotes early osteoblast differentiation and inhibits adipocyte differentiation in mouse bone marrow stromal cell lines that express estrogen receptor (ER) alpha or beta. *Endocrinology* 2002;143:2349–56.
- [27] Benglis D, Wang MY, Levi A. A comprehensive review of the safety profile of bone morphogenetic protein in spine surgery. *Neurosurgery* 2008;62:ONS423–31.
- [28] Kang Q, Song WX, Luo Q, et al. A comprehensive analysis of the dual roles of BMPs in regulating adipogenic and osteogenic differentiation of mesenchymal progenitor cells. *Stem Cells Dev* 2009;18:545–59.
- [29] Merrick MT, Hamilton KD, Russo SS. Acute epidural lipedema: a novel entity and potential complication of bone morphogenetic protein use in lumbar spine fusion. *Spine J* 2013;13:e15–9.
- [30] Zechner U, Kohlschmidt N, Kempf O, et al. Familial Sotos syndrome caused by a novel missense mutation, C2175S, in NSD1 and associated with normal intelligence, insulin dependent diabetes, bronchial asthma, and lipedema. *Eur J Med Genet* 2009;52:306–10.
- [31] Mayes JS, Watson GH. Direct effects of sex steroid hormones on adipose tissues and obesity. *Obese Rev* 2004;5:197–216.
- [32] Van Pelt RE, Gozansky WS, Hickner RC, Schwartz RS, Kohrt WM. Acute modulation of adipose tissue lipolysis by intravenous estrogens. *Obesity (Silver Spring)* 2006;14:2163–72.
- [33] Gavin KM, Cooper EE, Hickner RC. Estrogen receptor protein content is different in abdominal than gluteal subcutaneous adipose tissue of overweight-to-obese premenopausal women. *Metab Clin Exp* 2013;62:1180–8.
- [34] Mauvais-Jarvis F, Clegg DJ, Hevener AL. The role of estrogens in control of energy balance and glucose homeostasis. *Endocr Rev* 2012;34:309–38.
- [35] Lundholm L, Zang H, Hirschberg AL, Gustafsson JA, Arner P, Dahlman-Wright K. Key lipogenic gene expression can be decreased by estrogen in human adipose tissue. *Fertil Steril* 2008;90:44–8.
- [36] Price TM, O'Brien SN, Welter BH, George R, Anandjiwala J, Kilgore M. Estrogen regulation of adipose tissue lipoprotein lipase—possible mechanism of body fat distribution. *Am J Obstet Gynecol* 1998;178:101–7.
- [37] Simpson ER, Misso M, Hewitt KN, et al. Estrogen—the good, the bad, and the unexpected. *Endocr Rev* 2005;26:322–30.
- [38] Carr MC. The emergence of the metabolic syndrome with menopause. *J Clin Endocrinol Metab* 2003;88:2404–11.
- [39] Xu Y, Nedungadi TP, Zhu L, et al. Distinct hypothalamic neurons mediate estrogenic effects on energy homeostasis and reproduction. *Cell Metab* 2011;14:453–65.
- [40] Elias CF, Aschkenasi C, Lee C, et al. Leptin differentially regulates NPY and POMC neurons projecting to the lateral hypothalamic area. *Neuron* 1999;23:775–86.
- [41] Elmquist JK, Elias CF, Saper CB. From lesions to leptin: hypothalamic control of food intake and body weight. *Neuron* 1999;22:221–32.
- [42] Musatov S, Chen W, Pfaff DW, et al. Silencing of estrogen receptor in the ventromedial nucleus of hypothalamus leads to metabolic syndrome. *Proc Natl Acad Sci USA* 2007;104:2501–6.
- [43] Wenczl E, Daróczy J. Lipedema, a barely known disease: diagnosis, associated diseases and therapy. *Orv Hetil* 2008;149:2121–7.
- [44] Szolnoky G, Nemes A, Gavallér H, Forster T, Kemény L. Lipedema is associated with increased aortic stiffness. *Lymphology* 2012;45:71–9.
- [45] Jaafar H, Abdullah S, Murty MD, Idris FM. Expression of Bax and Bcl-2 in tumour cells and blood vessels of breast cancer and their association with angiogenesis and hormonal receptors. *Asian Pac J Cancer Prev* 2012;13:3857–62.
- [46] Rupnick MA, Panigraphy D, Zhang CY, et al. Adipose tissue mass can be regulated through the vasculature. *Proc Natl Acad Sci USA* 2002;99:10730–5.
- [47] Rutkowski JM, Davis KE, Scherer PE. Mechanisms of obesity and related pathologies: the macro- and microcirculation of adipose tissue. *FEBS J* 2009;276:5738–46.
- [48] Gealekman O, Burkart A, Chouinard M, Nicoloso SM, Straubhaar J, Corvera S. Enhanced angiogenesis in obesity and in response to PPARgamma activators through adipocyte VEGF and ANGPTL4 production. *Am J Physiol Endocrinol Metab* 2008;295:E1056–64.
- [49] Tan BK, Adya R, Chen J, et al. Metformin decreases angiogenesis via NF-(kappa)B and Erk1/2/Erk5 pathways by increasing the antiangiogenic thrombospondin-1. *Cardiovasc Res* 2009;83:566–74.
- [50] Suga H, Araki J, Aoi N, Kato H, Higashino T, Yoshimura K. Adipose tissue remodeling in lipedema: adipocyte death and concurrent regeneration. *J Cutan Pathol* 2009;36:1293–8.
- [51] de Kreutzenberg SV, Crepaldi C, Marchetto S, et al. Plasma free fatty acids and endothelium-dependent vasodilation: effect of chain-length and cyclooxygenase inhibition. *J Clin Endocrinol Metab* 2000;85:793–8.

- [52] Kim F, Tysseling KA, Rice J, et al. Free fatty acid impairment of nitric oxide production in endothelial cells is mediated by IKKbeta. *Arterioscler Thromb Vasc Biol* 2005;25:989–94.
- [53] Halberg N, Khan T, Trujillo ME, et al. Hypoxia-inducible factor 1alpha induces fibrosis and insulin resistance in white adipose tissue. *Mol Cell Biol* 2009;29:4467–83.
- [54] Cao Y. Angiogenesis modulates adipogenesis and obesity. *J Clin Invest* 2007;117:2362–8.
- [55] Birmingham JM, Busik JV, Hansen-Smith FM, Fenton JI. Novel mechanism for obesity-induced colon cancer progression. *Carcinogenesis* 2009;30:690–7.
- [56] Rathbun S, Heath PJ, Whitsett T. Images in vascular medicine. The venoarterial reflex. *Vasc Med* 2008;13:315–6.
- [57] Gollasch M, Dubrovskaja G. Paracrine role for periadventitial adipose tissue in the regulation of arterial tone. *Trends Pharmacol Sci* 2004;25:647–53.
- [58] Jagtman BA, Kuiper JP, Brakkee AJ. Measurements of skin elasticity in patients with lipedema of the Moncorps “rusticanus” type. *Phlebologie* 1984;37:315–9.
- [59] Amann-Vesti BR, Franzeck UK, Bollinger A. Microlymphatic aneurysms in patients with lipedema. *Lymphology* 2001;34:170–5.
- [60] Lohrmann C, Foeldi E, Langer M. MR imaging of the lymphatic system in patients with lipedema and lipo-lymphedema. *Microvasc Res* 2009;77:335–9.
- [61] Wollina U, Heinig B, Schönlebe J, Nowak A. Debulking surgery for elephantiasis nostras with large ectatic podoplanin-negative lymphatic vessels in patients with lipo-lymphedema. *Eplasty* 2014;14:e11. eCollection 2014.
- [62] Brorson H. Liposuction normalizes – in contrast to other therapies – lymphedema-induced adipose tissue hypertrophy. *Handchir Mikrochir Plast Chir* 2013;44:348–54.
- [63] Nougues J, Reyne Y, Dulor JP. Differentiation of rabbit adipocyte precursors in primary culture. *Int J Obes* 1988;12:321–33.
- [64] Langendoen SI, Habbema L, Nijsten TE, Neumann HA. Lipoedema: from clinical presentation to therapy. A review of the literature. *Br J Dermatol* 2009;161:980–6.
- [65] Schulte-Merker S, Sabine A, Petrova TV. Lymphatic vascular morphogenesis in development, physiology, and disease. *J Cell Biol* 2011;16:607–18.
- [66] Danussi C, Spessotto P, Petrucco A, et al. Emilin1 deficiency causes structural and functional defects of lymphatic vasculature. *Mol Cell Biol* 2008;28:4026–39.
- [67] Silha JV, Krsek M, Sucharda P, Murphy LJ. Angiogenic factors are elevated in overweight and obese individuals. *Int J Obes (Lond)* 2005;29:1308–14.
- [68] Jeltsch M, Kaipainen A, Joukov V, et al. Hyperplasia of lymphatic vessels in VEGF-C transgenic mice. *Science* 1997;276:1423–5.
- [69] Schneider M, Conway EM, Carmeliet P. Lymph makes you fat. *Nat Genet* 2005;37:1023–4.
- [70] Shin BW, Sim YJ, Jeong HJ, Kim GC. Lipedema, a rare disease. *Ann Rehabil Med* 2011;35:922–7.
- [71] Mansfeld G, Muller F. Der Einfluss der Nervensystem auf die Mobilisierung von Fett. *Arch Physiol* 1913;152:61–7.
- [72] Mauer MM, Bartness TJ. Short-day-like body weight changes do not prevent fat pad compensation after lipectomy in Siberian hamsters. *Am J Physiol* 1997;272:R68–77.
- [73] Faust IM, Miller Jr WH, Sclafani A, Aravich PF, Triscari J, Sullivan AC. Diet-dependent hyperplastic growth of adipose tissue in hypothalamic obese rats. *Am J Physiol* 1984;247:R1038–46.
- [74] Youngstrom TG, Bartness TJ. White adipose tissue sympathetic nervous system denervation increases fat pad mass and fat cell number. *Am J Physiol* 1998;275:R1488–93.
- [75] Adler ES, Hollis JH, Clarke IJ, Grattan DR, Oldfield BJ. Neurochemical characterization and sexual dimorphism of projections from the brain to abdominal and subcutaneous white adipose tissue in the rat. *J Neurosci* 2012;32:15913–21.
- [76] Ricardo JA, Koh ET. Anatomical evidence of direct projections from the nucleus of the solitary tract to the hypothalamus, amygdala, and other forebrain structures in the rat. *Brain Res* 1978;153:1–26.
- [77] Seeley RJ, Drazzen DL, Clegg DJ. The critical role of the melanocortin system in the control of energy balance. *Annu Rev Nutr* 2004;24:133–49.
- [78] Grill HJ. Distributed neural control of energy balance: contributions from hindbrain and hypothalamus. *Obesity (Silver Spring)* 2006;14:216S–21S.
- [79] Coimbra CC, Migliorini RH. Cold-induced free fatty acid mobilization is impaired in rats with lesions in the preoptic area. *Neurosci Lett* 1998;88:1–5.
- [80] Bagnasco M, Dube MG, Kalra PS, Kalra SP. Evidence for the existence of distinct central appetite, energy expenditure, and ghrelin stimulation pathways as revealed by hypothalamic site-specific leptin gene therapy. *Endocrinology* 2002;143:4409–21.
- [81] Lazzarini SJ, Wade GN. Role of sympathetic nerves in effects of estradiol on rat white adipose tissue. *Am J Physiol* 1991;260:R47–51.
- [82] Clegg DJ, Brown LM, Woods SC, Benoit SC. Gonadal hormones determine sensitivity to central leptin and insulin. *Diabetes* 2006;55:978–87.
- [83] Diano S, Kalra SP, Sakamoto H, Horvath TL. Leptin receptors in estrogen receptor-containing neurons of the female rat hypothalamus. *Brain Res* 1998;812:256–9.
- [84] Stallworth JM, Hennigar GR, Jonsson Jr HT, Rodriguez O. The chronically swollen painful extremity. A detailed study for possible etiological factors. *JAMA* 1974;228:1656–9.
- [85] El Darouti MA, Marzouk SA, Mashaly HM, et al. Lipedema and lipedematous alopecia: report of 10 new cases. *Eur J Dermatol* 2007;17:351–2.
- [86] Fair KP, Knoell KA, Patterson JW, Rudd RJ, Greer KE. Lipedematous alopecia: a clinicopathologic, histologic and ultrastructural study. *J Cutan Pathol* 2000;27:49–53.